

Non-otologic Dizziness

Timothy C. Hain, MD
Clinical Professor
Neurology, Otolaryngology, Physical
Therapy
Northwestern University, Chicago
t-hain@northwestern.edu

Dizziness is an imprecise term

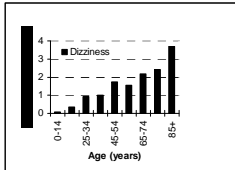
- Vertigo (sensation of motion)
- Lightheaded
- Ataxia
- Confusion



Because "Dizziness" is an imprecise term, a major role of the clinician is to sort patients

Dizziness is VERY Common

- Dizziness is the chief complaint in 2.5% of all primary care visits.
- 30% lifetime prevalence of dizziness requiring medical attention
- Older people have more dizzy problems



Estimated percentage of ambulatory care patients in whom dizziness was a primary complaint (Sloane, et. al., 1989).

Diagnostic Categories

Category

- Otological
- Neurological
- Medical
- Psychological
- Undiagnosed

Example

- Meniere's disease
- Migraine
- Low BP
- Anxiety
- Post-traumatic vertigo

Question 1

- Which category is associated with the most dizziness ?
 1. Inner ear disorders
 2. CNS problems (e.g. Stroke)
 3. Blood pressure
 4. Psychological problems
 5. Undiagnosed

Answer 1

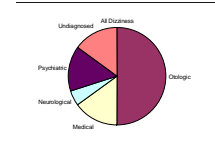
- It depends on your referral base
 1. Inner ear disorders (about 50% of ENT, 30% in general)
 2. CNS (about 25% of neurology, 5% everyone else)
 3. Blood pressure (30% of family practice, 5% everyone else)
 4. Psychological problems (15% to 50%)
 5. Undiagnosed (up to 50%)

Diagnostic Categories

- Neurological (i.e. posterior fossa)
- Medical
- Psychological (anxiety, malingering)
- Undiagnosed

Diagnostic Categories – non-otologic dizziness

1. Neurological (i.e. posterior fossa)
2. Medical (i.e. low blood pressure)
3. Psychological (anxiety, malingering)
4. Undiagnosed

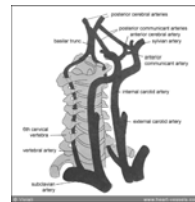


Causes of neurological dizziness 15-30% subspecialty, 5% ER

- 35% Stroke and TIA (% varies with practice)
- 16% Migraine (% varies with practice)
- Various Ataxias
- Seizures
- Multiple Sclerosis
- Tumors
- Head Trauma
- CSF pressure abnormalities - -CSF leak, NPH

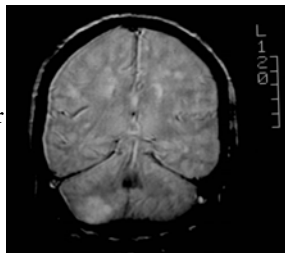
Carotid disease does NOT cause dizziness

- Carotids supply anterior brain. No dizziness circuitry there. Carotid disease causes weakness/numbness/speech disturbance
- Carotid endarterectomy rarely helps dizziness



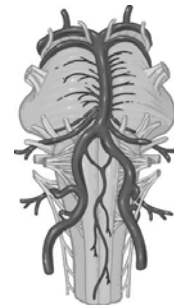Posterior Fossa stroke

- 50 year old doctor developed vertigo and unsteadiness
- Continued to operate for a week before seeking medical attention but wife wouldn't let him drive.
- PICA stroke seen on MRI



Common Strokes with Dizziness

- PICA (lateral medullary and cerebellum) – palatal weakness
- AICA (pons and cerebellum) – hearing loss
- SCA (cerebellar)



Posterior Inferior Cerebellar Artery (PICA)
Wallenberg's Syndrome
Lateral Medullary Syndrome

■ Adolf Wallenberg

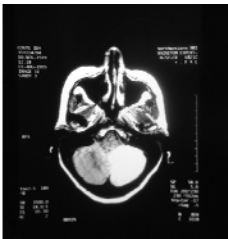
German internist, born November 10, 1862, Preuss.-Stargard. died 1949.



Case (IC)

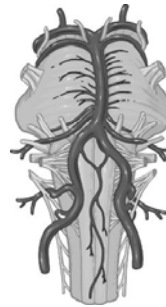- Onset of dizziness 1 week ago
- Unable to walk
- Diabetes and new onset a-fib
- Exam:
 - Ataxic but intact VOR
 - No spontaneous nystagmus
 - Neuropathy

Lateral Medullary Syndrome



- Most common “dizzy” stroke
- Generally lack clear localizing findings.
- MRI makes dx.

Lateral Medullary Syndrome

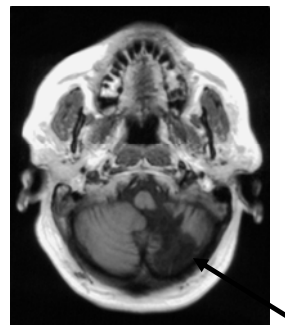


- Usually occluded vertebral

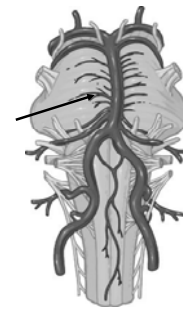
Basilar Artery syndrome (C.A.)

A 44 year old woman was involved in a rear end collision. She had a whiplash injury, and apparently the vertebral arteries in the neck were contused. Several days after the accident she became comatose, and studies suggested complete occlusion of the basilar artery.

Cerebellar infarct



Basilar artery



Basilar artery case findings (1991 vs. 2001)

- Unsteady Gait
- Finger to nose ataxia
- Nystagmus (eyes moving involuntarily)
- Same
- Same
- Same

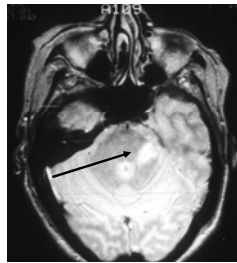
Basilar artery strokes are often fatal.

Common features of cerebellar gait ataxia

- Severe impairment of balance (worse than sensory balance disorders)
- Wide based gait
- Often refractory to treatment and time

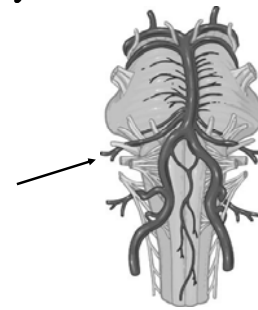
Anterior inferior cerebellar artery Case

- Woman with diabetes, obesity, hypertension suddenly becomes dizzy, and develops facial weakness in swimming pool.
- Brought into hospital and CT scan shows stroke in pons.



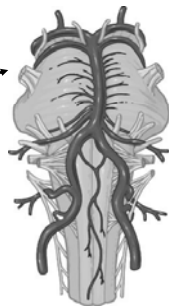Anterior inferior cerebellar artery AICA syndrome

- Rare stroke
- AICA supplies pons, cerebellum, 8th nerve
- Facial weakness
- Vertigo/hearing loss
- Incoordination



Superior Cerebellar Artery SCA Syndrome

- Rare stroke
- SCA supplies superior cerebellum and midbrain
- Ataxia and diplopia

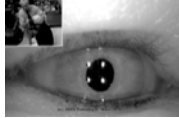


Paraneoplastic syndromes -- case

- 35 year old woman admitted to hospital because very unsteady – poor coordination
- Many tests were done without a diagnosis. Nobody did a breast exam.
- 1 year later noticed a large breast lump
- Breast cancer removed – but patient left with severe cerebellar syndrome

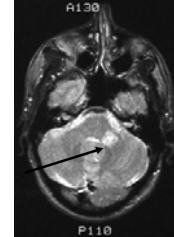
Paraneoplastic syndromes

- Remote effect of cancer
- Associated with lung and breast cancer
- Vestibulo-cerebellar syndrome – dominated by
 - Ataxia
 - Nystagmus (particularly downbeating)
- May be related to cellular immunity



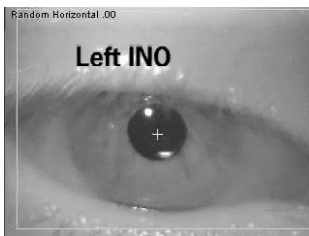Multiple Sclerosis (MS)

- No single pattern
- Multiple lesions distributed in time and space



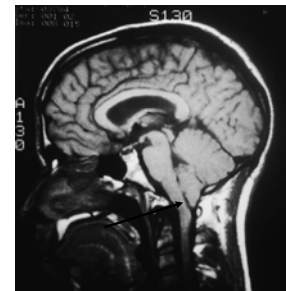
Multiple Sclerosis (MS)

- INO is common in MS

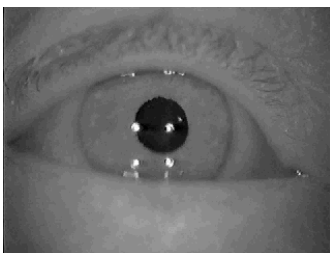

Chiari Malformation: Case

- Dock worker in Baltimore came in because gets dizzy when lifts heavy boxes
- Examination: unsteady, downbeating nystagmus.
- MRI showed cerebellar tonsils lower than normal.

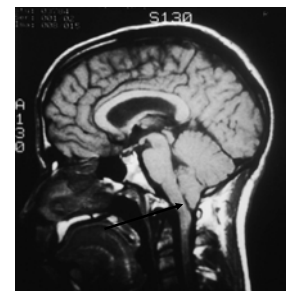


Downbeating Nystagmus may be clue to underlying cerebellar degeneration or Chiari



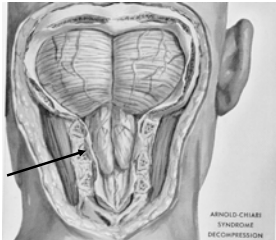
Chiari Malformation

- Cerebellar tonsils herniate downward
- Adult onset
- Straining or coughing produces headache or fainting
- Unsteadiness
- Nystagmus



Chiari Malformation
Treatment: Suboccipital decompression

Arrow points to tonsils. This surgical exposure is larger than would be used in real operation



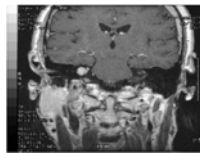
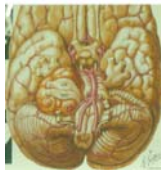Non-otologic ataxias – all of neurology ?

- Cerebellar
- Basal Ganglia
- Hydrocephalus
- Sensory loss (B12)
- Periventricular WM lesions
- CSF leak
- Drugs (e.g. anticonvulsants)
- Degenerations (e.g. PSP, Palatal myoclonus)

Brain Tumors Causing Dizziness

We worry a lot about these rare disorders

- Acoustic Neuroma (rare)
- Meningioma
- Cerebellar astrocytoma
- Cerebellar hemangioblastoma

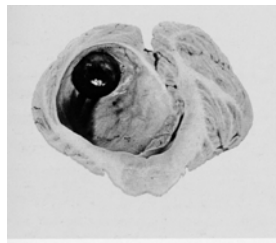


Cerebellar Astrocytoma Case

- Young woman in residency training
- Developed a headache and went to ER. In ER a CT scan was done.
- A large tumor was found occupying most of right side of cerebellum.
- Tumor was removed – after operation patient developed incoordination R side. Over 6 months, has improved so much can return to training program.

Cerebellar Astrocytoma

- Largely in children
- Slowly growing tumor
- Cerebellar hemisphere syndromes
- Resection often cures

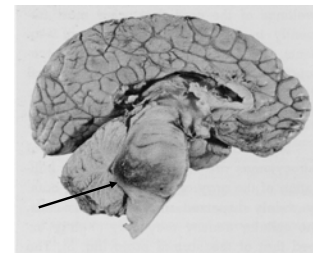


CYSTIC CEREBELLAR ASTROCYTOMA

Rubinstein L, Tumors of the Central Nervous System

Pontine Astrocytoma

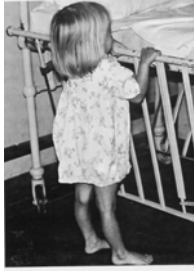- Largely in children
- Slowly growing tumor
- Affects cerebellar connections
- No treatment – fatal disease



PONTINE ASTROCYTOMA

Rubinstein L, Tumors of the Central Nervous System

This child is holding onto the bed rail due to ataxia from a medulloblastoma

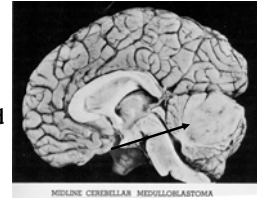


H.I. Cerebellar medulloblastoma

Severe ataxia
Strong positional nystagmus

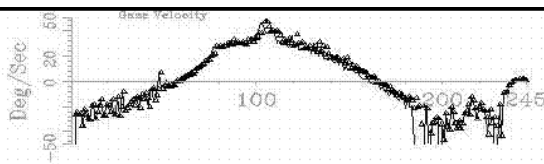
Cerebellar Medulloblastoma

- Mainly affects children
- Begins in cerebellar nodulus -- vestibulocerebellum
- Hydrocephalus (projectile vomiting) and cerebellar signs.
- Treat with resection, chemotherapy and radiation.
- 5 year survival – 80%



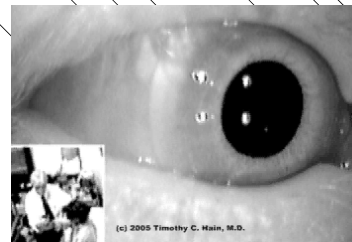
MIDLINE CEREBELLAR MEDULLOBLASTOMA

Periodic Alternating Nystagmus (PAN)



Congenital and acquired forms. Acquired form usually from cerebellar nodulus lesion (such as medulloblastoma). Usual period is 200 sec.

PAN – example (CN type)



(c) 2005 Timothy C. Hain, M.D.

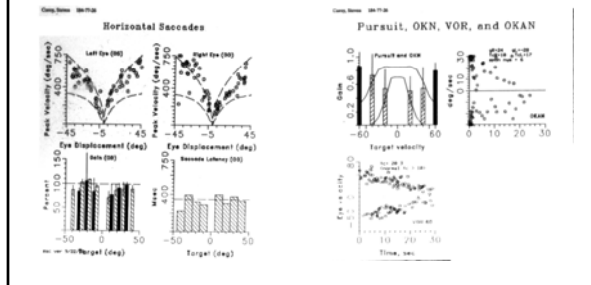
Treatment of Central Dizziness

- Vestibular Suppressants
- ? Agents that promote compensation
 - Betahistine, Amantadine, Baclofen
- Vestibular rehabilitation
- Environmental adaptations

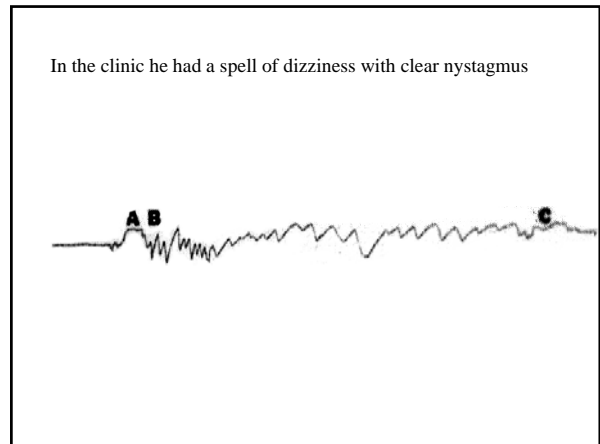
Case

- 8 Year old became dizzy playing video games
- Mother noted the eyes jumped
- Transient confusion

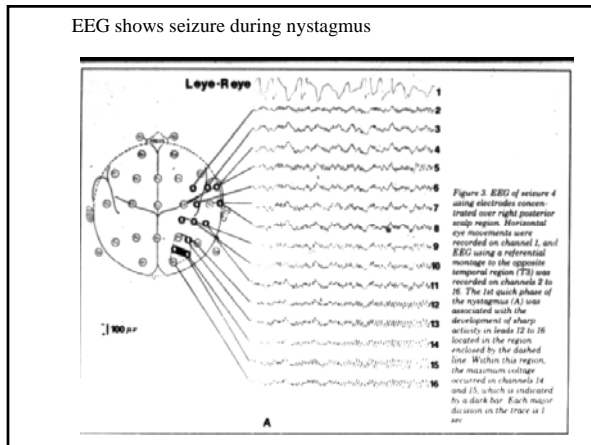
Normal Oculomotor and Vestibular Tests



In the clinic he had a spell of dizziness with clear nystagmus



EEG shows seizure during nystagmus



Seizures causing Dizziness

- Quick spins (1-2 seconds)
 - Also caused by vestibular nerve irritation
- Confusion and dizziness
- May be triggered by flashing lights
- Head injury is common
- Oxcarbamazine may stop them

Migraine & Vertigo: Prevalence

- Migraine:
 - 10% of U.S. population has Migraine†
 - 20-30% of women childbearing age
- Vertigo: 35% of migraine population.*
- Migraine + vertigo (MAV):
 - ~ 3.5% of U.S. pop.
 - ~ 10% of women of childbearing age

† Lipton and Stewart 1993; Stewart et al, 1994

*Kayan/Hood, 1984; Selby/Lance, 1960; Kuritzky, et al, 1981

Diagnosis of MAV Nystagmus

- No definitive pattern
- Often low amplitude downbeating or upbeating nystagmus
- ? Due to cerebellar disturbance

Diagnosis of MAV

Clinical judgment

- Headaches and dizziness
- Lack of alternative explanation (normal otological exam, neurological exam, CT)
- High index of suspicion in women of childbearing age. Perimenstrual pattern.
- Family history in 50%
- Response to prophylactic medication or a triptan

CSF pressure problems

Orthostatic symptoms

- CSF leak
 - Post-LP dizziness/nausea/headache
 - Post-epidural dizziness/hearing loss/tinnitus
 - Idiopathic
- No nystagmus

CSF-pressure problems

Normal pressure hydrocephalus

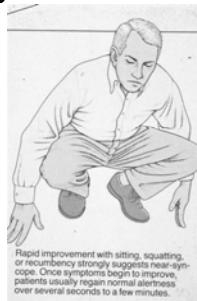- Ataxic/Apraxic gait
- No vertigo, hearing problems or cerebellar signs
- Respond to spinal tap followed by shunt

Diagnostic Categories

- Neurological (i.e. posterior fossa)
- Medical
- Psychological (anxiety, malingering)
- Undiagnosed

“Medical Dizziness” 30% of ER dizzy cases

- Cardiovascular (23-43%)
 - Orthostatic hypotension
 - Arrhythmia
- Infection (4-40%)
- Medication (7-12%)
- Hypoglycemia (4-5%)



Source: Madlon Kay (85), Herr et al (89)

Psychogenic Vertigo

Substantial – perhaps 20%

- Anxiety, hyperventilation, panic, Agoraphobia
- Somatization
- Malingering

Anxiety

- Long-duration dizziness
- Situational
- Responds to benzodiazepines
- Some have vestibular disorders too

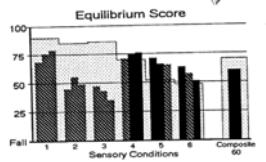


Somatization

- Chronic dizziness
- Numerous bodily ailments
- One goes away to be replaced by another
- We don't have a treatment for SD.
- Do not tell these people there is "nothing wrong". Rather, try to minimize the health-care cost.

We have several good tests for Malingering

- Moving Platform Posturography -- An algorithm for detecting inconsistency (Cevette score)

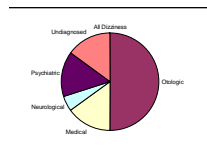


Undiagnosed Dizziness

- About 15% of all dizzy patients
- Our tests are not 100% sensitive
- We are not perfect either

Summary – non otologic dizziness

- Neurological (i.e. Migraine, posterior fossa)
- Medical (i.e. low blood pressure)
- Psychological (anxiety, malingering)
- Undiagnosed



More Details

Hain, T.C. Approach to the patient with Dizziness and Vertigo. Practical Neurology (Ed. Biller), 2002, 2007. Lippincott-Raven

More movies

www.dizziness-and-balance.com